

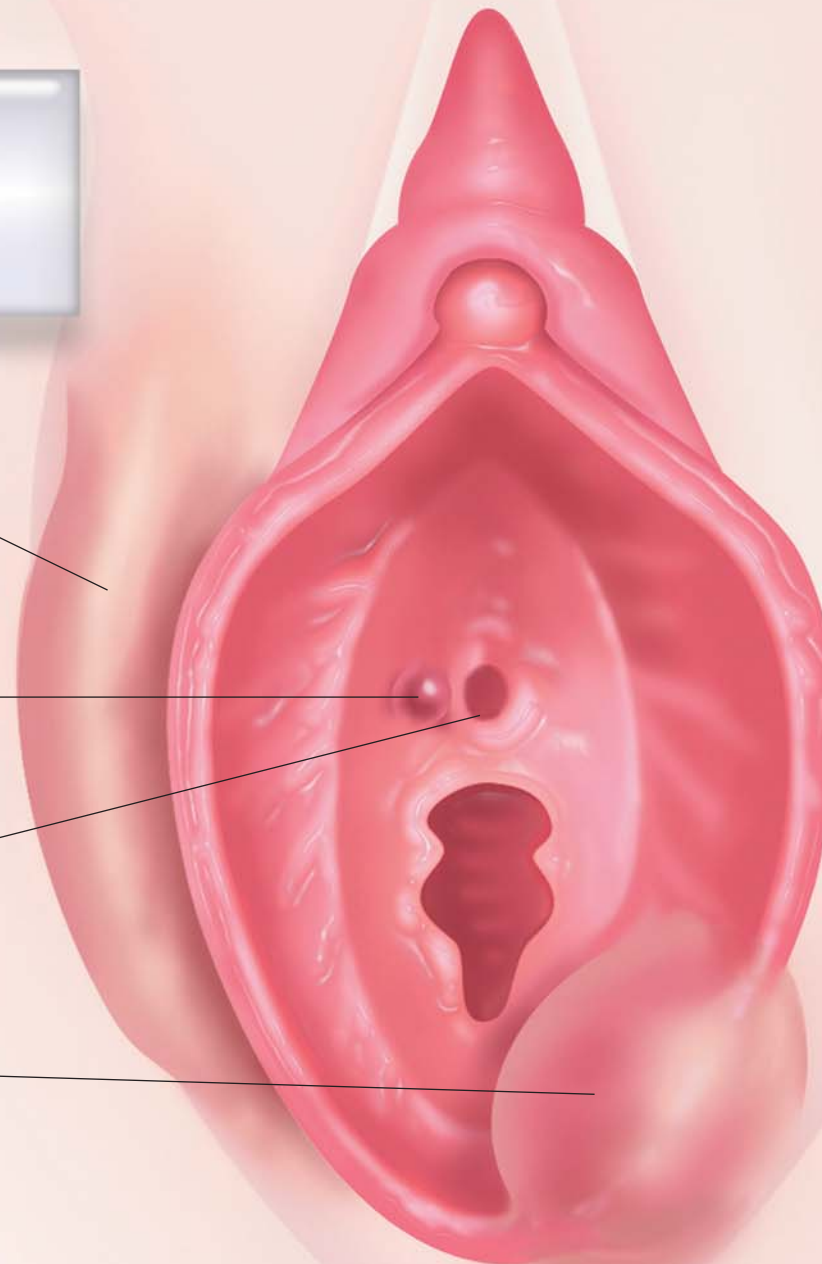
PATOLOGIA BENIGNA DELLA VULVA

*Cisti del dotto
di Nuck*

*Cisti parauretrali
di Skene*

Meato uretrale

*Cisti della ghiandola
di Bartolino*

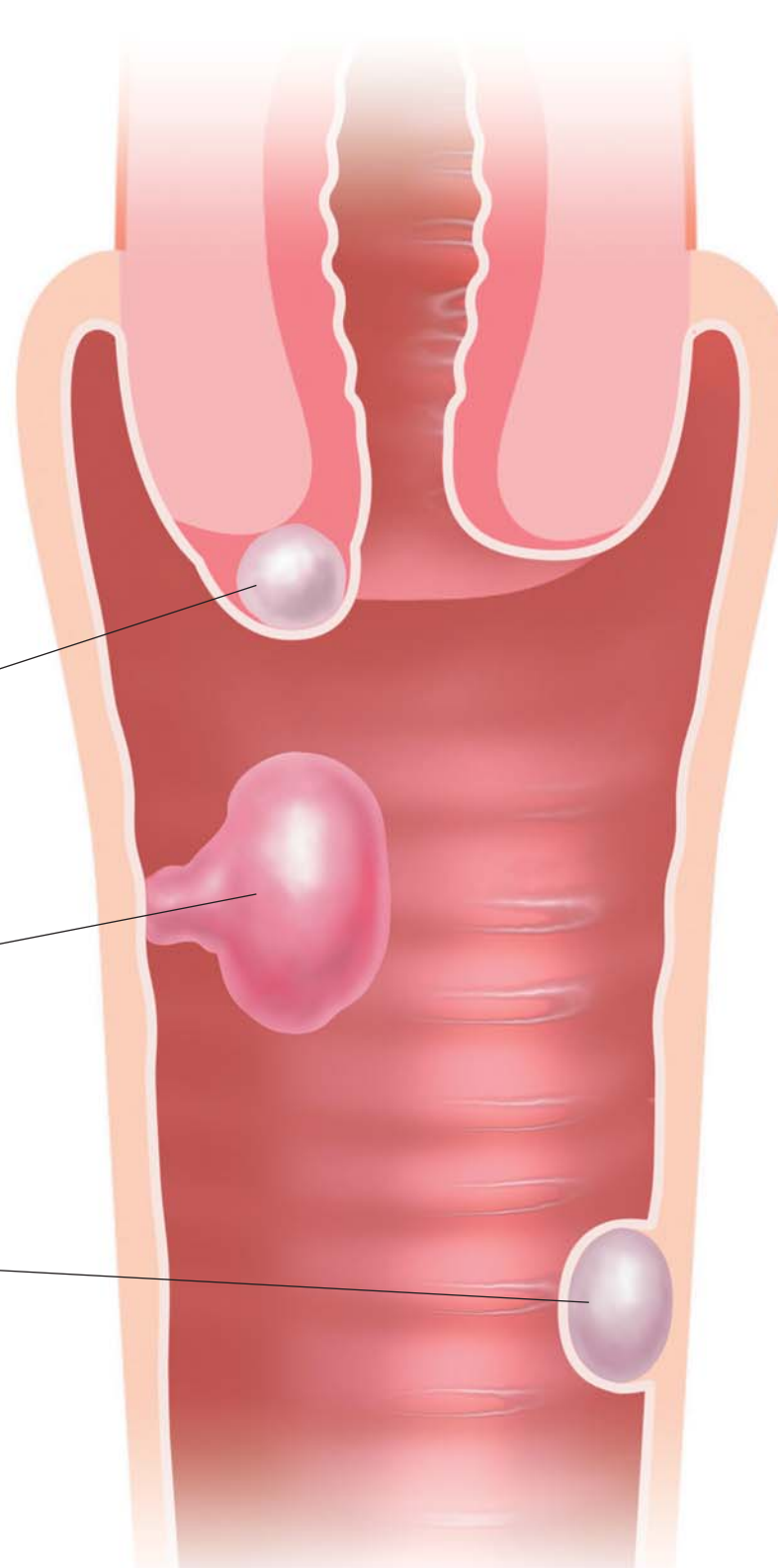


PATOLOGIA BENIGNA CERVICO-VAGINALE

Cisti di Naboth

Polipo vaginale

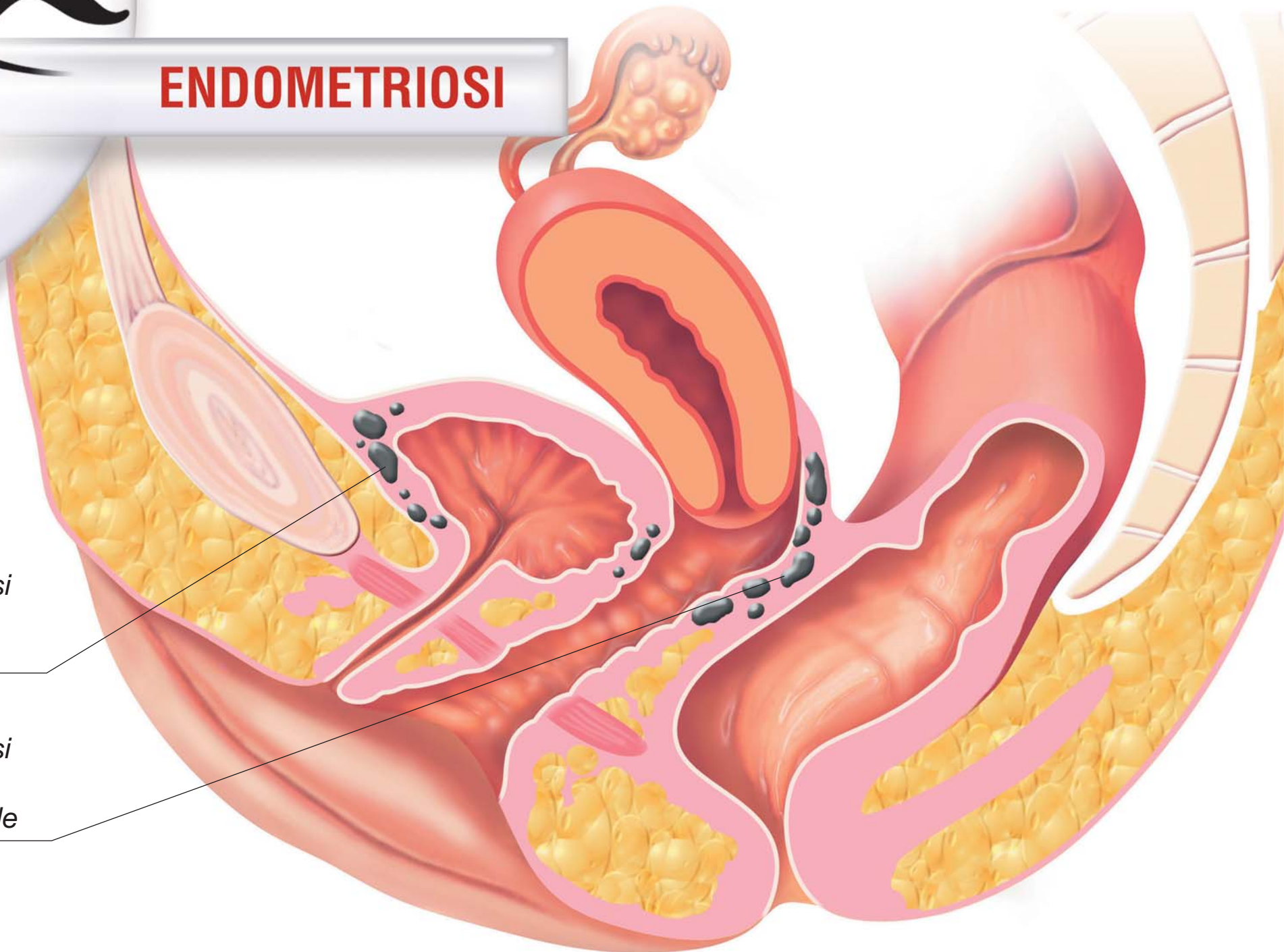
Cisti vaginale semplice



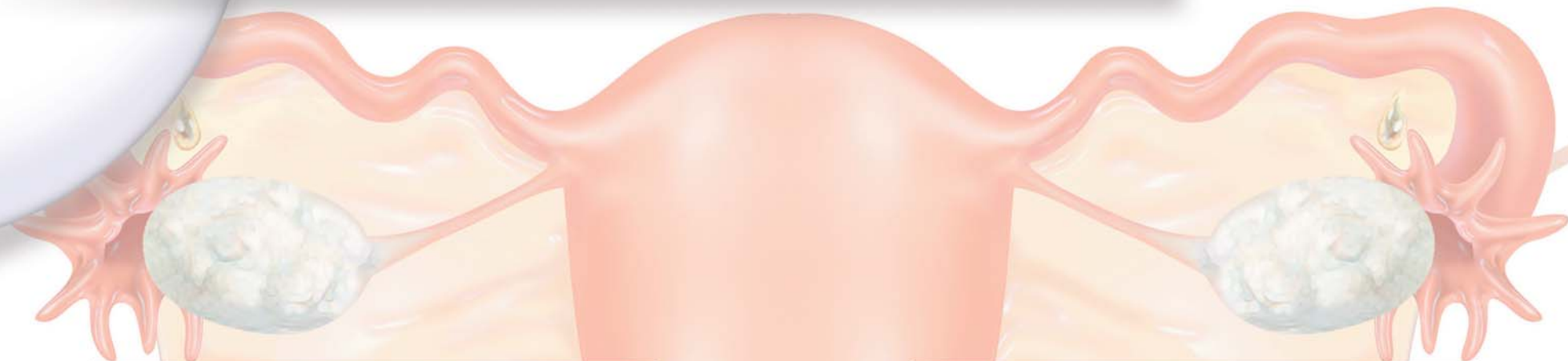ENDOMETRIOSI

*Endometriosi
della plica
vescicale*

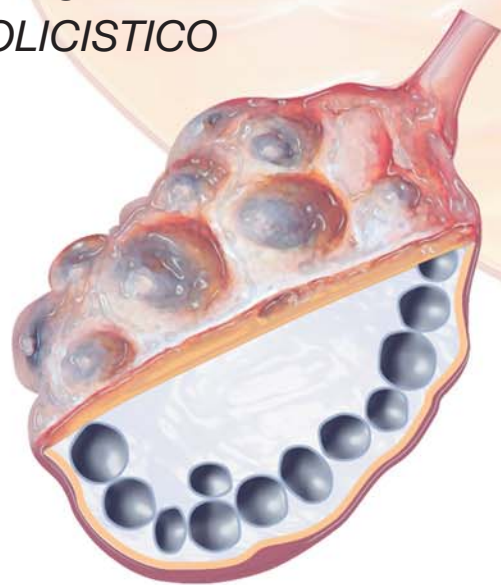
*Endometriosi
del setto
retto-vaginale*



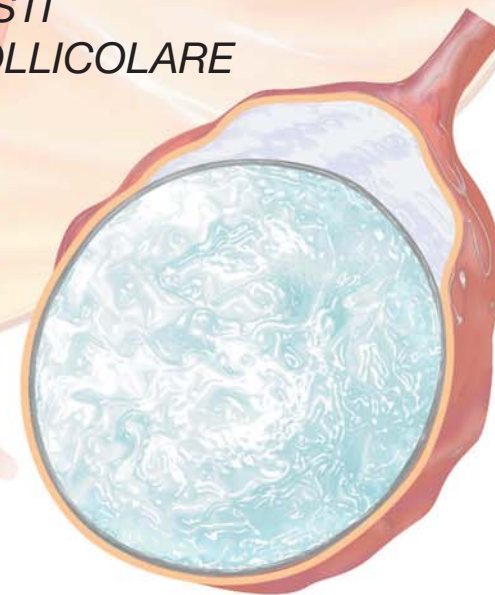
PATOLOGIA BENIGNA OVARICA



OVAIO
POLICISTICO

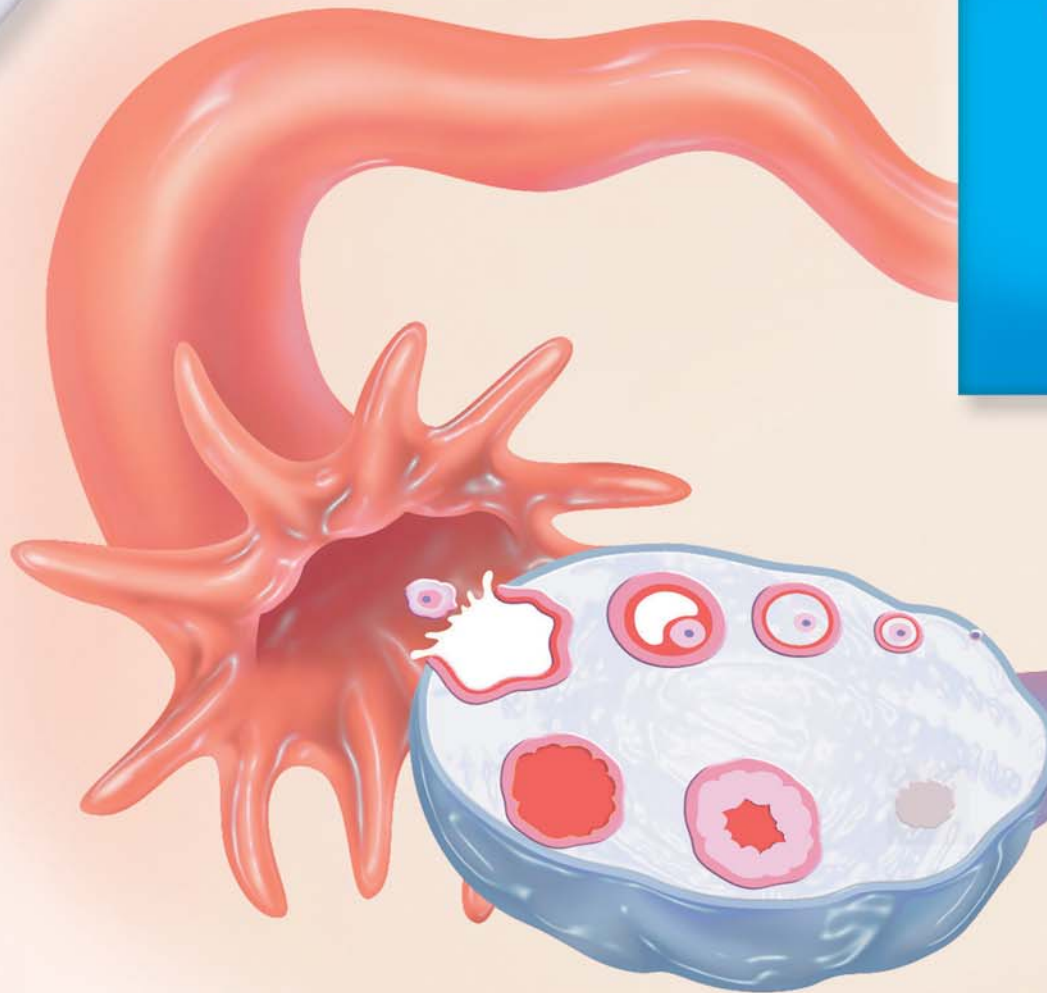
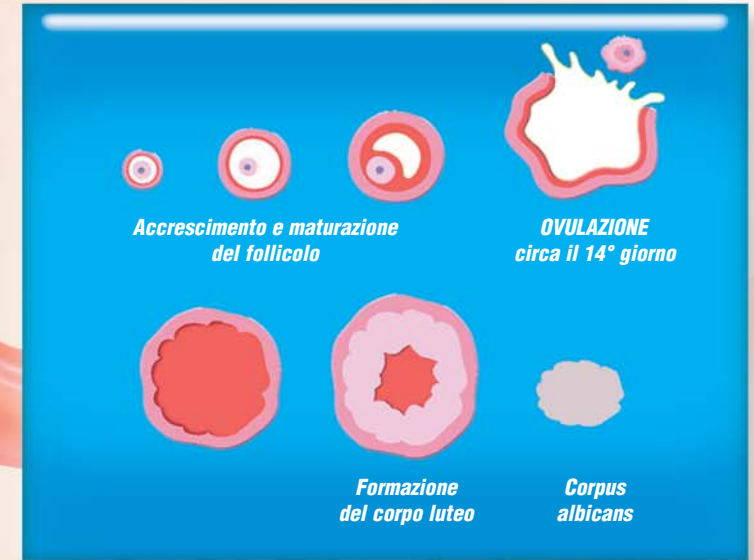

CISTI
FOLLICOLARE



CICLO OVARICO

O v u l a z i o n e

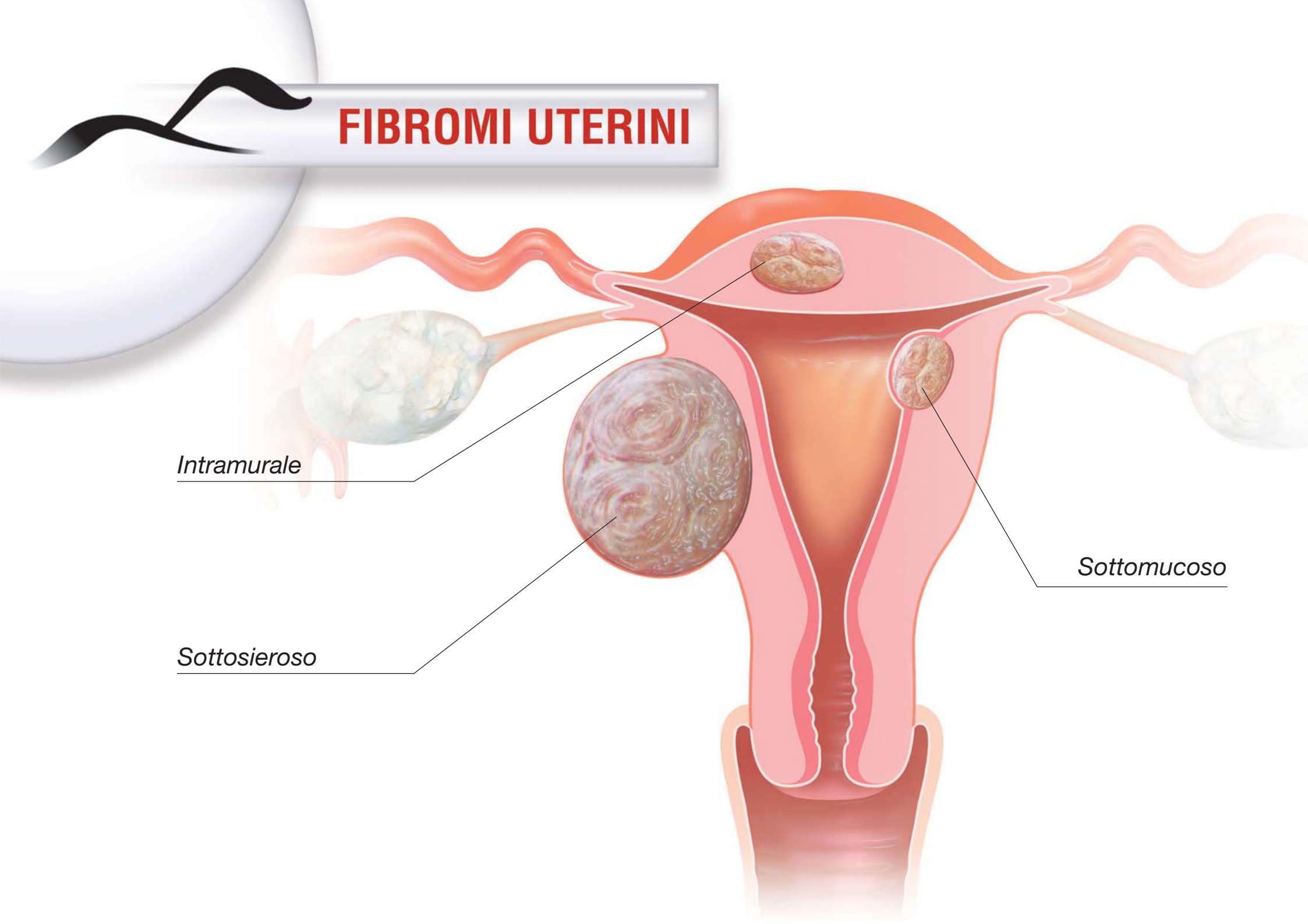


FIBROMI UTERINI

Intramurale

Sottosieroso

Sottomucoso

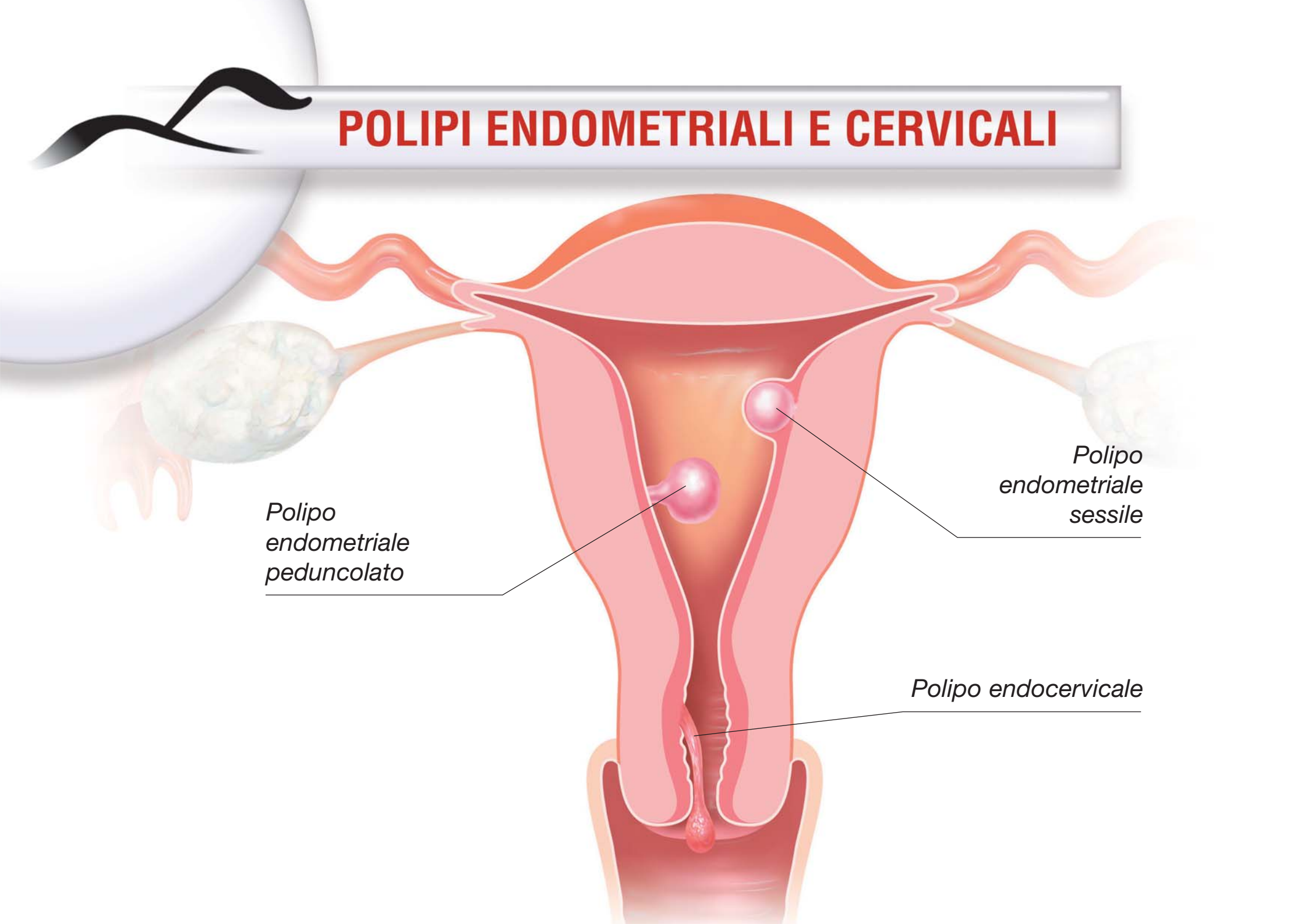


POLIPI ENDOMETRIALI E CERVICALI

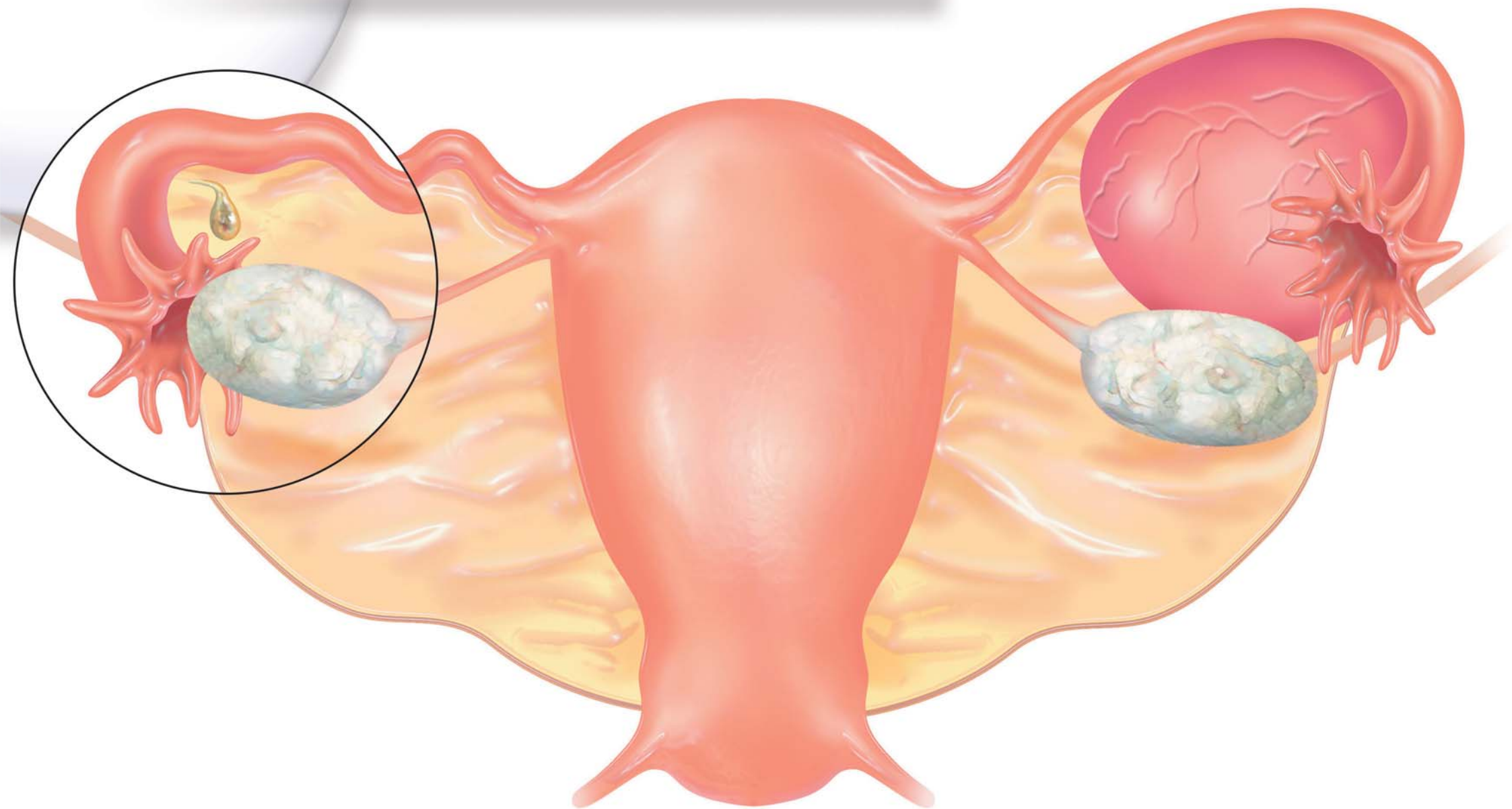
*Polipo
endometriale
peduncolato*

*Polipo
endometriale
sessile*

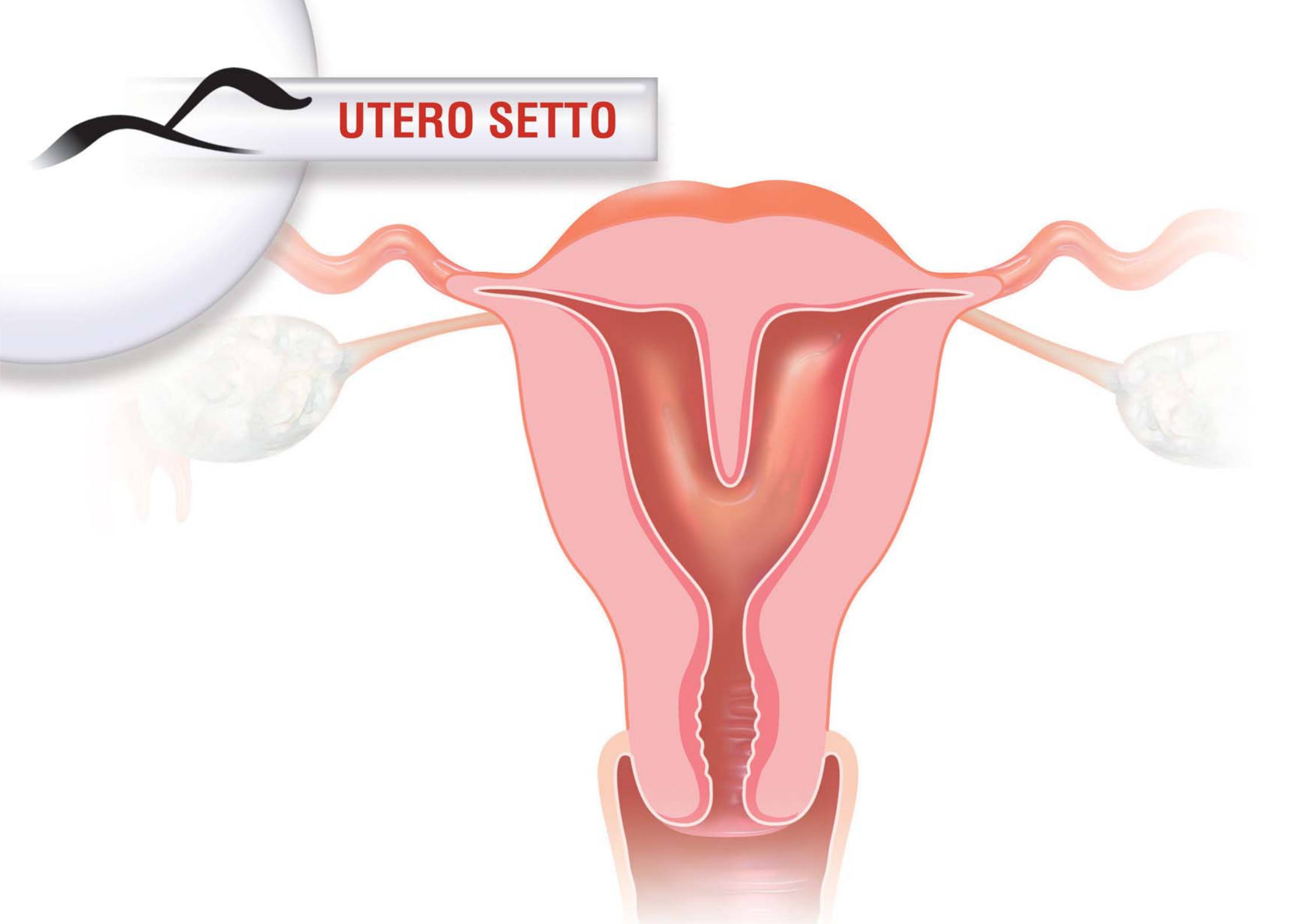
Polipo endocervicale



CISTI PARATUBARICA



UTERO SETTO



PROLASSI GENITALI

